

Primary Ependymoma of Ovary- A Rare Case Report

Maji Debajyoti^{1a}, Patel Apurva^{2a}, Panchal Harsha³, Parikh Sonia², Shah Kajal⁴, Gupta Yuganshu^{1b}, Reddy Goutham^{1c}

Senior Resident¹, Professor and Head of Unit², Prof and Head of Department³, Assistant Professor⁴
Department of Medical Oncology,

The Gujarat Cancer & Research Institute, Asarwa, Ahmedabad, Gujarat

Corresponding Author: shilpa.patel@gcriindia.org

 <https://orcid.org/0009-0004-4621-4992>^{1a}

 <https://orcid.org/0000-0002-3330-3679>³

 <https://orcid.org/0000-0003-2381-0391>^{2a}

 <https://orcid.org/0009-0003-7655-4165>^{1b}

 <https://orcid.org/0000-0002-9425-3580>^{2b}

 <https://orcid.org/0009-0005-0822-1355>^{1c}

Summary

Ependymoma is a glial tumor characterized by its differentiation towards ependymal cells, typically originating from the central nervous system. Primary ovarian ependymoma is an exceedingly uncommon entity with no established treatment protocol. Here we report a case of a young female who presented with ovarian mass. Initial imaging was suggestive of cystic mass arising from the right ovary. Tumor markers were negative. Patient underwent right salpingo-oophorectomy. The histopathological diagnosis of primary ovarian ependymoma was determined based on the strong expression of glial fibrillary acidic protein (GFAP), AE1, S100, and epithelial membrane antigen (EMA) observed in IHC. Patient was then treated with Etoposide based adjuvant chemotherapy. After 9 months of treatment patient is doing well with no evidence of disease. Although rare, this diagnosis should be kept in mind as a differential diagnosis of ovarian mass in a young female.

Keywords: Ependymoma, ovarian tumor, ovarian germ cell tumor

Introduction

Ependymoma is a glial tumor characterized by both neuro-ectodermal and ependymal differentiation, primarily found in the central nervous system. While extracranial and extraspinal ependymomas are exceedingly rare, they have been documented in various locations such as ovary, broad ligament, presacral and sacrococcygeal region, lung and mediastinum.¹ Compared to their CNS counterparts, extracranial ependymomas generally have a more favorable prognosis.^{2,3} Primary ovarian ependymoma is an extremely rare form of ovarian cancer, with approximately 35 reported cases in medical literature to date. Due to the scarcity of these cases, there is currently no established treatment strategy for these tumors. In this report, we present a case of an 18-year-old female who presented with ovarian ependymoma. She underwent salpingo-oophorectomy followed by adjuvant chemotherapy.

Case Report

An 18-year old young unmarried female presented with abdominal pain and discomfort since 2

months. Her past medical history was unremarkable. Initially, USG was performed and it showed a 16x13x9 cm cystic hypo-echoic lesion arising from the pelvis with right ovary not seen separately from the lesion. Consequently, abdominal CT scan was done which showed 17x16x13 cm well defined multi-loculated cystic lesion with internal heterogeneously enhancing solid component, arising in the right adnexa. Right ovary is not seen separately from the lesion. (Figure 1)

All routine blood tests and serum tumor markers like CA125, HE4, β HCG, AFP, CEA, and LDH were within normal limits. She underwent exploratory laparotomy with right salpingo-oophorectomy with omental biopsy. Intra-op frozen report of right adnexal mass showed a solid cystic mass with multiple papillary projections and histomorphologically two possibilities were suspected as 1) Cystic teratoma with area of ependymoma (Monodermal teratoma) and 2) Sex cord stromal tumor. On final HPE report, grossly 17x13x10 cm solid exophytic mass with adherent cyst wall was seen in right adnexa. External surface of the adnexal tumor was bosselated with nodular areas and outer surface was encapsulated. On cut surface it had solid cystic brownish tan with multiple papillary projections seen. On final histology, adnexal mass had sieve-like appearance and cystic spaces lined by pseudo-stratified columnar cells. Many areas showed bipolar fibrillary processes forming perivascular pseudo-rosettes and occasional true rosette formation (Figure 2). No other germ cell components were seen. Fallopian tube and omental biopsy were free of tumor. Peritoneal wash cytology was negative. Lymphovascular emboli was absent. After histopathological examination, a provisional diagnosis of primary monodermal teratoma-ovarian ependymoma was made. IHC showed positivity of AE1 (focal positive), EMA (dot like positive), GFAP (positive),

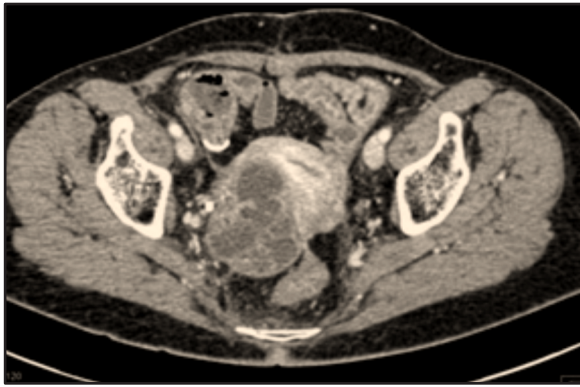


Figure 1: CT scan showing right adnexal mass.

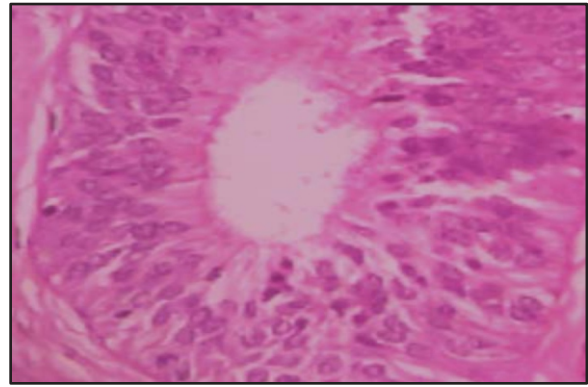


Figure 2: H&E stain showing ependymal rosette formation.

S100 (positive), Inhibin (occasional positive) and negative for synaptophysin, AFP, OCT3/4, CK7 with MIB index 8-10%. Post-op imaging showed no evidence of disease at operated site. MRI brain and spine showed no CNS lesions. Patient then received adjuvant chemotherapy with BEP regimen. Patient is now on regular follow up for last 9 months. She is now doing well with no complaint.

Discussion

Ependymoma is a glioma characterized by both neuro-ectodermal and ependymal differentiation, typically originating in the central nervous system. As per the WHO histological classification of Ovarian Tumors, ovarian ependymomas fall under the category of neuro-ectodermal tumors. Within the ovary, PNETs are divided into three classes: (1) differentiated tumors consisting of ependymoma, oligodendroglioma and astrocytoma; (2) primitive tumors encompassing neuroblastoma, ependymblastoma, medulloblastoma, neuroectodermal tumors, and medullo-epithelioma; and (3) anaplastic type comprising glioblastoma multiforme.^{3,4} While ependymomas primarily develop in the brain, extra-neural ependymomas often arise from remnant parts or displaced nests of the neural tube present in other organs. Ependymomas of the ovary, para-ovarian tissue, posterior mediastinum, omentum and lungs are very uncommon. Primary ovarian ependymomas typically affect individuals between the ages of 6 and 60 years, with a higher incidence seen in young patients, presenting unilaterally and without extra-ovarian involvement.⁵ Our patient, a young female, also presented with unilateral involvement. In the literature, though these tumors commonly manifest unilaterally.⁵ Few bilateral cases have been documented with extension into other pelvic organs.^{6,7}

The exact histo-pathogenesis of ovarian ependymomas remains unknown. Unlike other neuro-ectodermal tumors of the ovary, primary ovarian ependymomas rarely coexist with teratomas. Ovarian neuro-ectodermal tumors can resemble several primary and metastatic ovarian tumours.⁸ Initially, the presentation often mimics more common ovarian malignancies such as epithelial carcinoma and germ cell tumors. In our case, due to the patient's young age, a germ cell tumor like yolk sac tumor was excluded based on histology and IHC, which demonstrated the lack of hyperchromasia, irregularly formed nuclei, limited presence of mitotic figures, and absence of AFP staining, with normal serum AFP level. Other potential differential diagnoses included ovarian serous carcinoma, endometrioid carcinoma, granulosa cell tumor, and Sertoli-Leydig cell tumor.⁹ Definitive diagnoses were reached based on typical histological findings such as rosette formation, fibrillary cytoplasm, strong positivity for GFAP and S100 on IHC, and WT1, PAX 8, AFP and inhibin being negative, along with normal serum markers.

The standard treatment protocol for ovarian ependymoma is yet to be defined. Most cases described in the literature, underwent surgery and adjuvant therapy. In a recently published study, a stage III patient survived for 8 years following treatment with oral etoposide only.¹⁰ Hence, the authors concluded that etoposide-based therapy could impede the growth of ependymomal tumors and is worth considering post-surgery. In several other cases, the BEP chemotherapy regimen was utilized. Our patient also received BEP-based chemotherapy. Ovarian ependymomas generally exhibit a more favorable prognosis in terms of recurrence-free survival and overall survival when compared to their CNS counterparts. In the present case, our patient remained asymptomatic and was doing well 9 months after completing treatment.

Conclusion

Primary ovarian ependymoma is an uncommon tumor and exhibits significantly improved prognosis compared to CNS ependymoma. Therefore, it is crucial to consider it in the differential diagnosis of ovarian neoplasms, particularly among younger females. While there is no established treatment protocol, surgical intervention followed by adjuvant chemotherapy appears to hold promise as an effective approach for managing advanced ovarian ependymoma.

Declaration of patient consent

The patient has provided consent for clinical data to be documented in the journal. The individual acknowledges that her name and personal details will not be disclosed. Reasonable measures will be taken to safeguard her privacy; however, complete anonymity cannot be ensured.

Conflicts of interest

Nil

References

1. Takano T, Akahira J, Moriya T, et al: Primary ependymoma of the ovary: a case report and literature review. *International Journal of Gynecological Cancer* 2005; 15:1138-1141
2. Carlsson B, Havel G, Kindblom Lg, et al: Ependymoma of the ovary: A clinicopathologic, ultrastructural and immunohistochemical investigation: A case report. *APMIS* 1989;97:1007-1012
3. Aguirre P, Scully RE. Malignant neuroectodermal tumor of the ovary, a distinctive form of monodermal teratoma: report of five cases. *The American journal of surgical pathology* 1982; 6:283-292
4. Tavassoli FA, Devilee P. Pathology and genetics of tumours of the breast and female genital organs. World Health Organization Classification of Tumors, 3rd edn: IARC Press, 2003
5. Katz SY, Cachia D, Kamiya-Matsuoka C, et al: Ependymomas arising outside of the central nervous system: A case series and literature review. *Journal of Clinical Neuroscience* 2018; 47:202-207
6. Kleinman GM, Young RH, Scully RE. Ependymoma of the ovary: report of three cases. *Human pathology* 1984; 15:632-638
7. Kleinman GM, Young RH, Scully RE. Primary neuroectodermal tumors of the ovary. A report of 25 cases. *The American journal of surgical pathology* 1993; 17:764-778
8. Liang L, Olar A, Niu N, et al: Primary glial and neuronal tumors of the ovary or peritoneum: a clinicopathologic study of 11 cases. *The American journal of surgical pathology* 2016; 40:847
9. Carr KA, Roberts JA, Frank TS. Progesterone receptors in bilateral ovarian ependymoma presenting in pregnancy. *Human pathology* 1992; 23:962-965
10. Bell DA, Woodruff JM, Scully RE. Ependymoma of the broad ligament. A report of two cases. *The American journal of surgical pathology* 1984; 8:203-209